

# **Cervical Discogenic Myelopathy (C4-5, C5-6) Treated Successfully with Cox<sup>®</sup> Decompression Adjustment**

## **CASE HISTORY:**

On February 27, 2004, a female patient presented to me with a chief complaint of numbness in the lower half of her body, which started from the lower torso (T-10 level) and encompassed her lower extremities bilaterally. The patient stated that this condition started approximately 2 years ago beginning with numbness in her lower left extremity, which has progressed to now include numbness and motor weakness in both lower extremities. Initially, the patient was seen by her primary care physician, who referred her to a local vascular surgeon for the evaluation of a right adrenal neoplasm and to rule out a circulatory cause for her complaints. Subsequently, the patients' condition started to progress, so she was referred to a local neurologist, who in turn referred her to a neurologist at the University of Pennsylvania in order to rule out any demyelinating diseases or cord compression. The patient was referred for MRI studies of the cervical, thoracic and lumbar spine with EMG studies of the lower extremities. After establishing the absence of any demyelinating process or cord compression, the patient was told that she may have a small spinal cord tumor which has not yet surfaced and was left to fend for herself. The patient is married, a mother of two sons and is an active professional who works with her husband. At this time, the patient presented to me for evaluation and treatment recommendations for her condition.

## **HEALTH HISTORY:**

The patient has a past history of high blood pressure, diabetes for the last 6 months and allergies. She does not use tobacco or alcohol and uses caffeine moderately. The patient has a history of an auto accident approximately 10 years ago where she was thrown through the windshield of her car and stated that she had no formal residual complaints from this event.

## **PRESENT COMPLAINTS:**

Presently, the patient is complaining of numbness from her mid to lower torso which extends down to her lower extremities bilaterally. Muscle weakness in the lower extremities bilaterally and recently began to notice muscle weakness in her right hand. The patient experiences electric shock type pain intermittently which radiates down her spine and sometimes into her lower extremities which occurs mostly at night.

## **PHYSICAL EXAMINATION:**

The patient is a 43 year old female, who is 5'7" tall and weights 240 pounds. The patient was observed to have a limping gait using a cane to ambulate and was unsteady getting on and off the adjusting table. Observation of the skin about the head, neck and trunk was normal. Peripheral pulses of the upper and lower extremities were equal bilaterally. Palpation of the lymph nodes in the neck and axilla was within normal limits. Palpation for muscle spasms, pain and tenderness in the cervical and lumbar spine was within normal limits with some tenderness noted in the mid thoracic spine (T-6 to T- 9).

## **ORTHOPEDIC EXAMINATION:**

Cervical Compression, Maximum Cervical compression, Cervical Distraction, Soto-Hall, Valsalva, Tinels and Phalens were within normal limits.

Minor's sign was absent, Bechterew's, Valsalva, Bechterew's/Valsalva, Kemp's, Spinal Tilt, Neri Bow, Lewins,

SLR, Braggard's, Medial Hip Rotation, Lindner's, Patrick's, Yeoman's, Ely's, Nachlas's, Popliteal fossa Pain and Prone Lumbar Flexion were all negative.

#### NEUROLOGICAL EXAMINATION:

Patellar and Achilles deep tendon reflexes were a +3, bilaterally with Babinski's being absent bilaterally. Triceps, Biceps and brachioradialis deep tendon reflexes were a +1 in the right upper extremity and +2 in the left upper extremity. An inverted radial reflex was observed in the right forearm. (editor note of clarification: the inverted radial reflex is finger flexion instead of supination or flexion at the elbow when tapping the styloid of the radial bone. It indicates a lesion of the spinal cord affecting the fifth or sixth cervical segments. Hoffmann's reflex compliments it and is the flexion of the fingers when snapping the fingertips of the index or ring fingers and indicates corticospinal tract disease. It is also called Tromner's sign) Light touch sensation was noted to be within normal limits in the upper extremities, bilaterally and reduced throughout lower extremities dermatomes, bilaterally. There was an absence of pain in the cervical and lumbar spine throughout this examination. A positive Lhermitte sign was noted upon flexion of the cervical spine.

#### MUSCLE STRENGTH EXAMINATION:

Cervical spine flexion, extension, lateral flexion, bilaterally and rotation, bilaterally was within normal limits. Deltoid, Biceps, Triceps, Interossei, wrist extension and wrist flexion were noted to be weak in the right upper extremity and normal in the left upper extremity. The patient is right hand dominant having grip strength of 10 pounds in the right hand and 40 pounds in the left hand.

Dorsi-flexion, Plantar-flexion, Hallux flexion/extension, Foot eversion, Gluteus Maximus, Biceps Femoris and Quadriceps were all noted to be weak in the lower extremities, bilaterally.

#### SPINAL RANGES OF MOTION:

Cervical spine ranges of motion were within normal limits and without pain. The lumbar spine ranges of motion were also within normal limits; however the patient found it very difficult to perform the lumbar ranges of motion due to lower extremity numbness and motor weakness. She had to support herself using the wall of the examination room in order to stand. The ranges of motion of the shoulders were within normal limits, bilaterally.

#### RADIOLOGICAL REPORTS:

MRI of the cervical spine without contrast dated 9-4-03. Impression: Disc protrusions and extrusion as noted above at C4-5, C5-6, and C6-7 without evidence of cord impingement. Examination is otherwise negative. No evidence of abnormal enhancement. Figure 1 is the sagittal image showing disc degeneration and protrusion of the C5-C6, C6-C7 and C7-T1 intervertebral disc levels. Figure 2 reveals the central C6-C7 disc protrusion with high intensity changes within the disc material.

MRI study of the thoracic spine dated 9-18-03. Impression: Very minor degenerative spondylotic changes of the vertebral endplates in the lower thoracic spine.

Upper extremity evoked potential examination dated 9-29-03. Impression: Normal upper extremity somatosensory evoked potential. No evidence of a lesion in the ascending somatosensory pathways.

Lower extremity evoked potential examination dated 9-29-03. Impression: Abnormal lower extremity somatosensory evoked potential due to prolongation of the left cortical response. Given the normal upper extremity SSEP, this is consistent with a lesion involving the somatosensory pathways in the thoracic spinal cord on the left.

MRI study of the thoracic spine dated 11-11-03. Impression: Probable right adrenal neoplasm. Minimal indentation of the anterior aspect of the cord at T6-7 due to a small disc protrusion and at T8-9 due to disc bulging. No cord lesion identified.

**CLINICAL OPINION:**

My clinical impression at this time is that this patient has a cervical discogenic myelopathy. Although her cervical spine MRI study of 9-4-03 does not show cord impingement, her physical examination has classic signs of this condition. That being upper motor-neuron signs in the lower extremities (hyper-reflexia and spasticity) with lower motor-neuron signs in the upper right extremity (hyporeflexia and weakness). There were deficits in fine movement with unsteadiness from tandem walking. Abnormal sensory findings with patterns of decreased dermatomal sensations were present. There was a positive Lhermitte sign and an inverted radial reflex in the right upper extremity. A differential diagnosis to rule out MS, spinal cord tumor, congenital brain stem malformation, myopathies and neuropathies was performed. From a chiropractic stand point, the patient is a well nourished 43 year old female, she is a professional, a wife and mother of 2 sons, leads a very active life. A structural evaluation reveals that she has an extreme case of forward head translation and spends a significant amount of time in flexion of the cervical spine. My impression is that her body weight pulls her head and upper body forward creating cord pressure in the cervical spine aggravated by the protruded and extruded discs present in the cervical spine. The patient was given a treatment plan of Cox Decompression Adjusting specifically decompressing the C4-C5 and C5-C6 discs using only long y-axis traction at 3xs per week for a 4 week period with a re-examination performed upon completion of this treatment plan. She was also encouraged to supplement her diet with glucosamine sulfate and chondroitin sulfate, daily. Tolerance testing was performed and it was noted that the patient was unable to tolerate decompression manipulation in the thoracic or lumbar spine as it would send pain shooting into her lumbar spine and extremities. After 2 weeks of specific long y-axis distraction to her cervical spine, the patient regained muscle strength and started to walk without the aid of a cane. After 4 weeks the patient started to regain feeling in her lower extremities. Unfortunately, upon regaining feeling in her lower extremities it was discovered that the patient has sustained a fracture to a left metatarsal which has to be surgically corrected. To date, the patient has been treated 27 times spanning 4 months. She has lost 40 pounds and will begin a home exercise program as soon as her left foot heals from the surgery. Presently, she still walks without a cane and is still regaining feeling in her legs and torso. She is starting to regain strength in her right upper extremity which to date has doubled (grip strength from 10 to 20 lbs). She is now being treated on an as needed basis. Since she is "back from the brink" of physical disability, she is a very motivated patient and my opinion is that as she loses more weight and reconditions her body her prognosis is very good.

Respectfully submitted,  
Ted Siciliano, DC

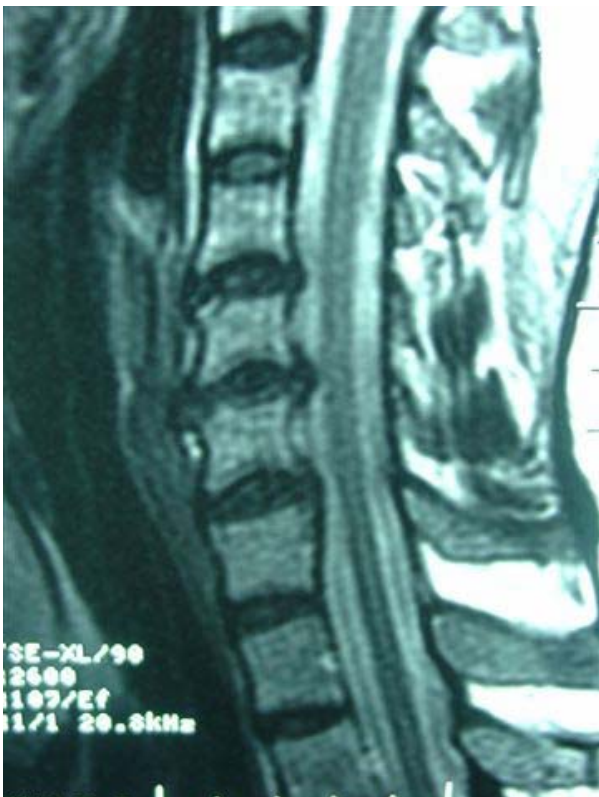

Figure 1

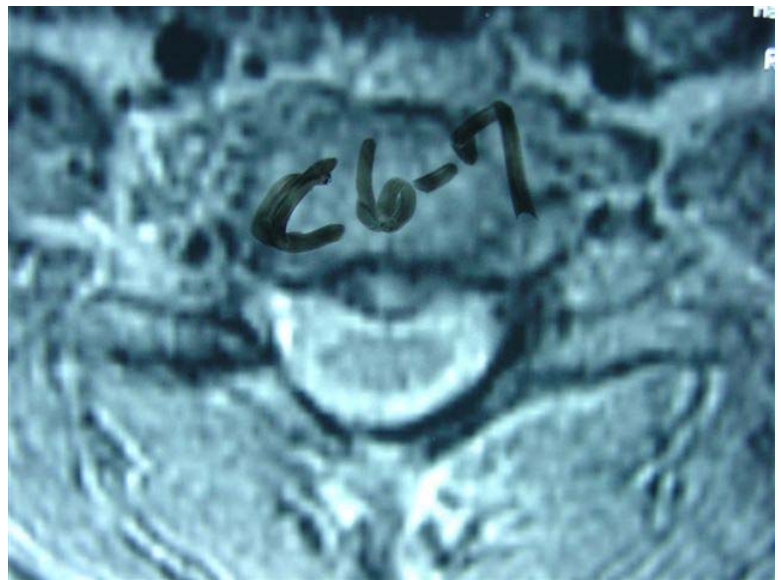


Figure 2